

From Our Office to Yours...

Dental implant maintenance is often a confusing topic and clear guidelines have been lacking. Many of the guidelines and protocols provide conflicting or out of date information, and/or are often not based on sound research.

The American Academy of Periodontology has provided a position paper on dental implant maintenance, which concludes that "every practice needs to change to employ special methods that monitor and maintain dental implant health, and determine inflammatory complications, as part of an ongoing periodontal maintenance program."

In this current issue of The PerioDontaLetter, we provide recommendations for peri-implant monitoring, personal plaque control methods, and in-office maintenance techniques to reduce the incidence of peri-implant disease.

As always, we welcome your suggestions and comments.

Clinical Practice Recommendations for the Maintenance of Implant-Based Restorations

Dental implants have proven to be a reliable replacement for natural teeth, but their shape and contours are very different from natural teeth.

There are many different implant-supported restorations, many of which retain plaque to varying degrees, and are difficult to access to effectively remove bacterial plaque.

It is clear that implants require entirely different methods of

plaque control than natural teeth. We cannot always apply to dental implants the same methods we have used for the past century for home care and professional in-office maintenance for natural teeth.

Peer-reviewed published literature indicates that the incidence of peri-implant disease may be as high as twenty percent after seven years in function. Patients who have systemic

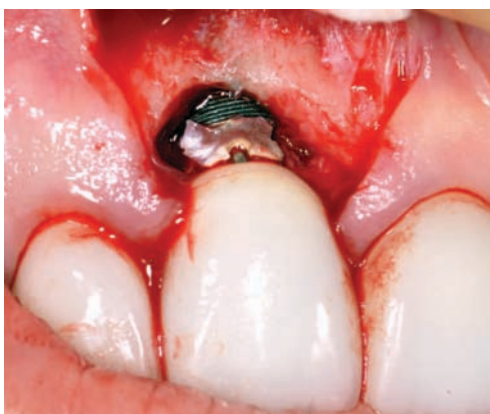

Figure 1. Failure to remove subgingival cement has created a very uncertain prognosis for this implant.

risk factors, including diabetes and smoking, exhibit an even greater incidence of peri-implant disease.

It is incumbent upon the dental team to develop customized methods of plaque removal and to encourage a regular schedule of in-office visits for implant maintenance.

Implant Assessment

According to the 2017 World Workshop of the American Academy of Periodontology (AAP) and the European Federation of Periodontology (EFP), classic signs of peri-implantitis are: plaque-associated inflammation, probing

depths (PD) greater than 4–5mm, and progressive bone loss (BL) greater than 2–3mm.

The findings indicated that conversion to peri-implantitis was strongly correlated with poor plaque control, bleeding on probing, probing depths and lack of regular maintenance.

The presence of uncontrolled periodontitis associated with natural teeth was also correlated to peri-implantitis.

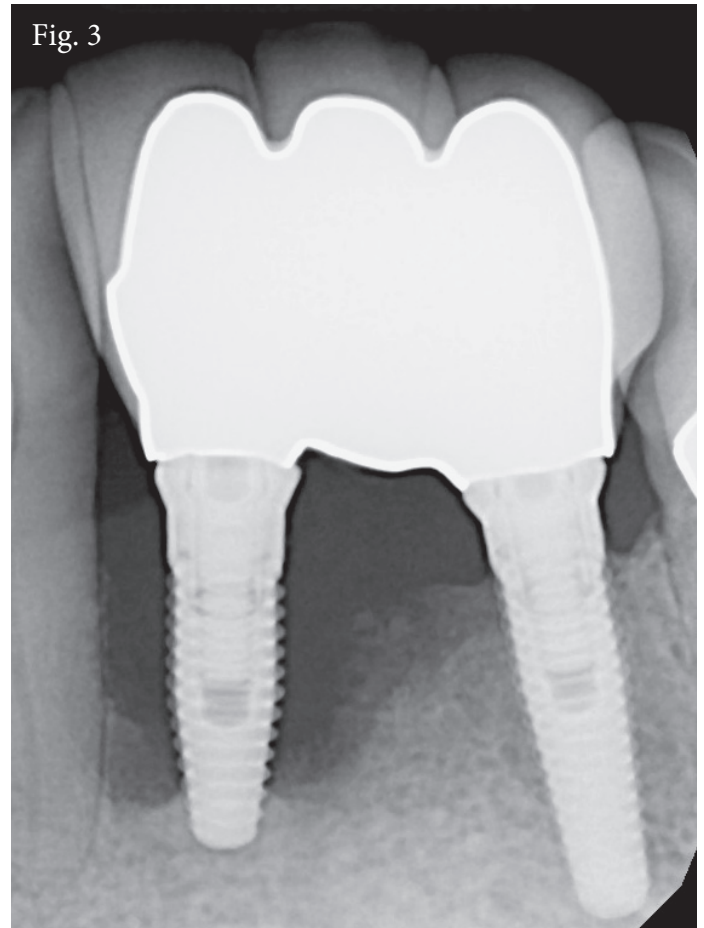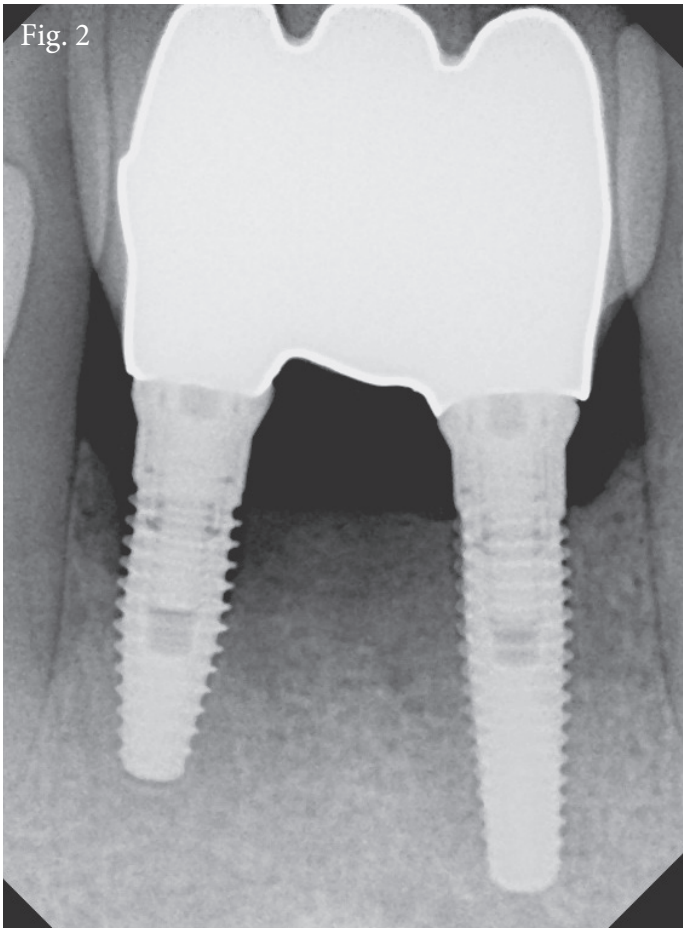
It is critical that implants not be placed in patients with uncontrolled periodontitis, and it is critical to assess overall oral health when implant supported restorations are planned.

It is advised that clinicians placing dental implants assess the level of

dental health at the time of contemplated implant surgery. This provides a baseline against which to compare progressive changes in the status of the implants. It is suggested that peri-implant health and radiographic bone levels be documented within three to six months of implant restoration.

At the time of office visits for implant maintenance, the following should be carefully evaluated:

- Overall peri-implant tissue health
- Effectiveness of plaque control
- Inflammatory changes and exudate when probing or palpating peri-implant tissues
- The presence of calculus or residual cement



Figures 2 and 3. This patient chose to try to maintain the implant without any therapeutic intervention. Three years later, the implant has failed, and resultant massive bone loss creates minimal treatment options.

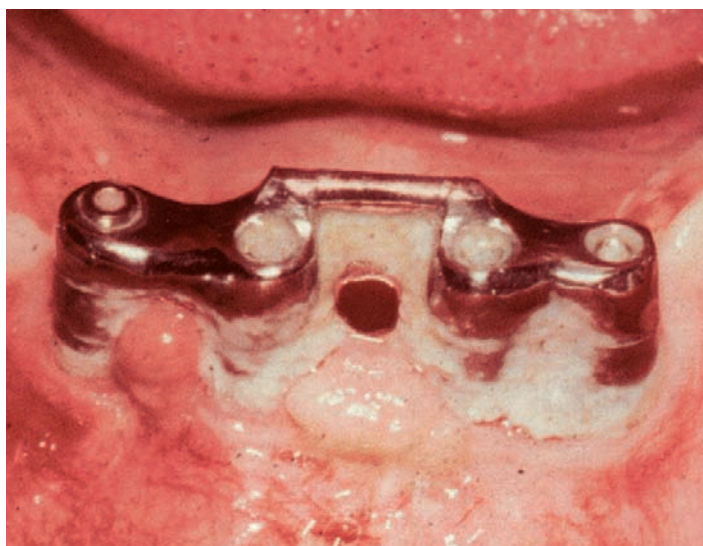


Figure 4. Implants are tremendously successful, but not without patient cooperation. In addition to inadequate home care, the lack of attached gingiva creates a significant risk factor.

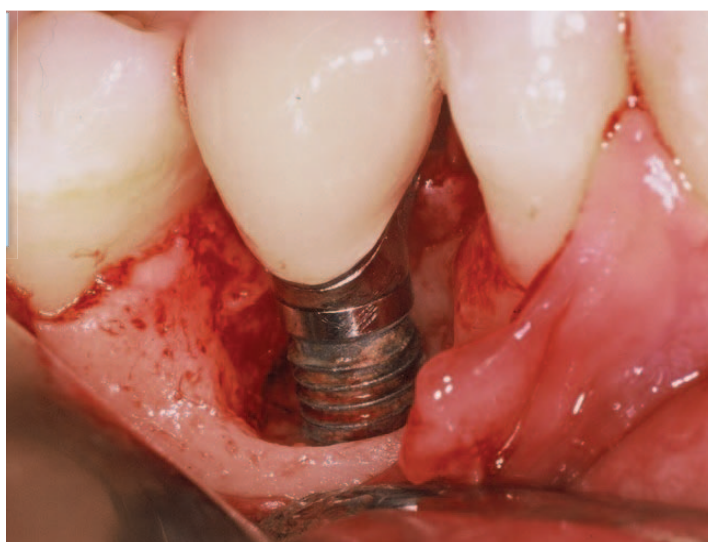


Figure 5. Therapeutic intervention is complicated by the presence of implant threads and a roughened implant surface. Removal of the biofilm is critical to stabilize or create new bone.

- Mobility or pain
- Evidence of radiographic bone loss
- Presence or lack of adequate keratinized gingiva
- Excessive occlusal forces
- Condition of the prosthesis, including wear, chipping or fractures
- Optimal function

An ongoing systematic approach to the evaluation of implant health will ensure early recognition of peri-implant disease, permitting rapid clinical intervention.

It is recommended that full-arch fixed restorations be removed once a year to assess the status of the supporting tissues and the prosthesis.

When the prosthesis is removed, it is possible to observe contours that make plaque removal difficult, and permit corrections to be made. At this time, it is further recommended to replace the retentive screws. If adverse occlusal forces are noted, an occlusal guard may be recommended.

Professional Maintenance

Instrumentation

Once the loss of attachment reaches the level of the threads, ordinary stainless-steel instruments can be used to clean the implant since they are already corroded. Some clinicians prefer titanium instruments or diamond-coated ultrasonic inserts.

A scientific panel of numerous professional dental organizations, together with the American Dental Association (ADA), recently published clinical practice guidelines for implant maintenance.

This panel found that the evidence strongly supports the use of glycine-based subgingival air polishers around dental implants, and dental implant supported prostheses.

These air polishers use glycine powder which dissolves within the peri-implant sulcus, or pockets, and

without eliciting a host-inflammatory response. The powder is placed around the implant subgingivally and then drawn out slowly and activated to decontaminate the implant surface.

Because implant surfaces are often rough, these air polishers allow debridement of the implant surface more thoroughly than other available methods. The focus is on the removal of biofilm from the entire implant surface.

Polishing and Fluoride

Implant, abutment and restorative surfaces can be safely polished with a rubber cup and prophylaxis paste. The prophylaxis paste chosen should have minimal abrasiveness to protect the surfaces from further damage.

If fluoride is being used to protect surrounding natural teeth, the choice of a pH neutral sodium fluoride will minimize titanium corrosion. At times, anti-microbial, chlorhexidine-thymol varnish may be helpful.

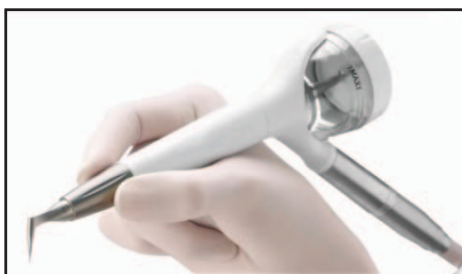

Figure 6. Glycine-based subgingival air polishers debride the implant surface more thoroughly than other available methods.

Home Care

Electric toothbrushes are recommended for implants and implant supported prosthetic devices. Interdental brushes without twisted metal centers are effective in plaque removal.

Regardless of the type of prosthesis, brushing twice a day is recommended. Rather than trying to brush a removable appliance, which is not usually effective, dropping it in a solution of denture cleanser or chlorhexidine twice a week will work more effectively.

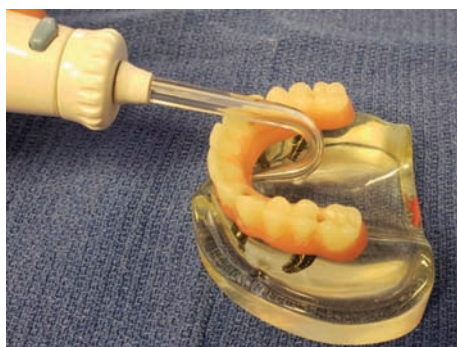

Figure 7. Irrigation tips can be heated to customize them for better patient access for home care compliance.

Water Irrigators

Water irrigating devices are useful, especially when delivering antimicrobials, such as chlorhexidine or diluted ordinary household bleach, to the implants and any adjacent teeth.

Water irrigator tips can be modified by heating them up and bending them into a curve in order to access the palatal/lingual surfaces of implant restorations. These areas are often difficult to access using standard tips because of the angle of the implant.

Rinses and Topical Agents

Mouth rinses may help maintain peri-implant health. Most published articles recommend the use of

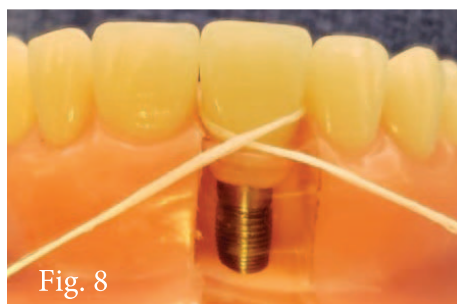


Fig. 8

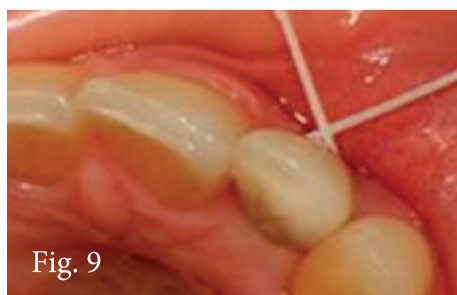

Fig. 9

Figures 8 and 9. In contrast to natural teeth, criss-cross (shoeshine) flossing can be very effective for plaque control around implants.

chlorhexidine when peri-implant inflammation is observed, in addition to debridement and other improved personal plaque control measures.

For a patient who has invested in an implant to replace a missing tooth or teeth, regular, effective maintenance, in addition to regular checks of the retentive elements, with replacement as needed, is critical to long-term success.

Flossing

The “criss-cross” flossing technique can help remove plaque biofilm subgingivally around implants more effectively than the technique used to floss natural teeth.

Using this technique, the floss is placed through both contacts, mesial and distal, then crossed over at the buccal.

Flossing is then performed in a shoe-shine like motion around the implant. Non-woven floss is recommended for this technique, as woven floss may shred and leave behind fibers.

Conclusion

It should be impressed on every dental implant patient that, like teeth, dental implants are subject to the progression of inflammatory disease.

Consequently, regular and more importantly, effective disease control methods, as well as regular professional care, is essential to maintaining long-term dental health.

